




HEART FAILURE
ASSOCIATION OF INDIA

QUIZ 2
December 2020



Quiz of the Month Series

Win attractive prizes.

5000 INR for the Winner

**Last date of submission
December 31st 2020**

Rules of the Quiz.

1. This is an image based Quiz. The images which are related to heart failure will be followed by the queries
2. The participant should give the correct answer and provide explanation for that answer in 50 words.
3. The Quiz Master will select the First person who had given the correct answer with the correct explanation (Depending on the time received in our server).
4. The decision of the Quiz master is final and no further deliberations in any form are allowed.
5. The winner will get a digital certificate and a Cash Prize of 5000 INR.



The Quiz of December 2020 is by **Dr. Syamkumar Divakara Menon**, who is Associate Professor of Medicine. Faculty of Health Sciences, McMaster University Director, Adult Cardiac Electrophysiology Fellowship Program Arrhythmia services, Hamilton Health Sciences, Hamilton, ON, Canada.

Dr Syamkumar Divakara Menon graduated from Medical College Calicut and had MD in Internal medicine from the same medical school. He got enrolled in the DM Cardiology program of Sree Chitra Institute, Trivandrum (SCTIMST) and subsequently worked as faculty in Cardiology at Medical College Calicut. Completed fellowship in Cardiac Electrophysiology from McMaster University, Hamilton, ON and Asklepios Klinik ST Georg Hamburg. He then joined McMaster University as faculty in the division of cardiology in 2008 and is currently Associate professor, Dept of medicine and staff cardiologist and electrophysiologist at Hamilton Health Sciences. Completed MSc in health sciences education in 2013. He is actively involved in teaching and clinical research with Best Teacher Award and many publications.

QUIZ 2

DECEMBER 2020

A 21 year old previously healthy woman presented with history of shortness of breath of NYHA class 2-3 severity, tiredness and mild postural dizziness of 2 days duration . Physical examination revealed a heart rate of 130 beats per minutes, stable blood pressure of 90/60 mm of Hg. She had features of mild heart failure with an elevated jugular venous pressures of 8 cms in the sitting position, muffled heart sounds with a 3rd sound gallop and bilateral basilar rales. 12 lead ECG is take at admission shown in Fig 1. An Echocardiogram performed is shown in Movie Clip 1.

She underwent a definitive interventional procedure and the post ECG and Echo are given in Panel 2.(Figure 2 and Movie Clip 2)

Fig 1: ECG at admission

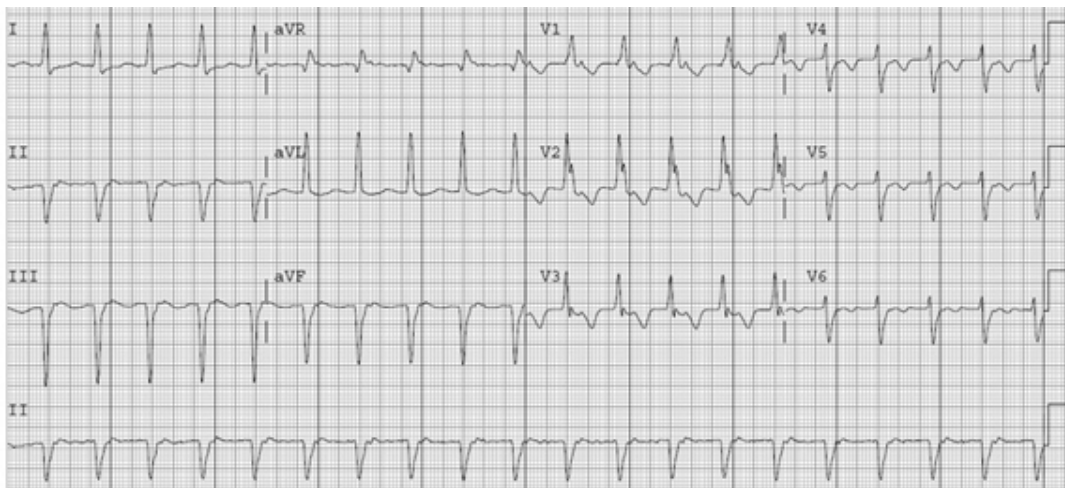
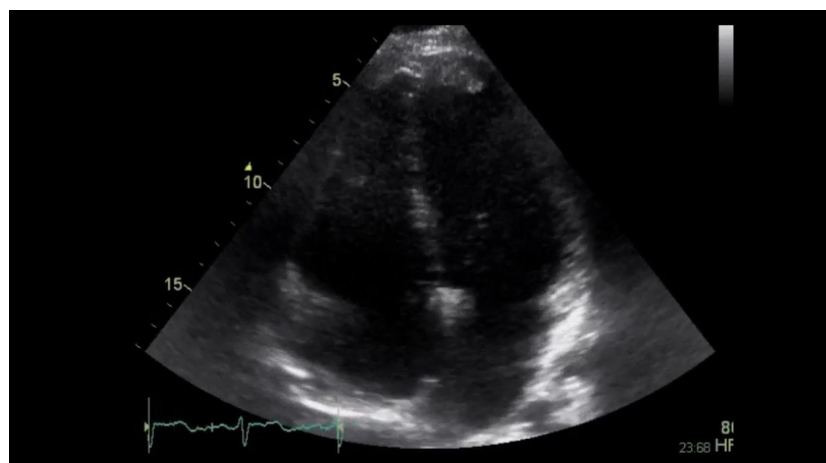


Figure 1 - Echocardiogram basal



To see the video click on the link

CLICK HERE



Figure 2 - ECG Post intervention

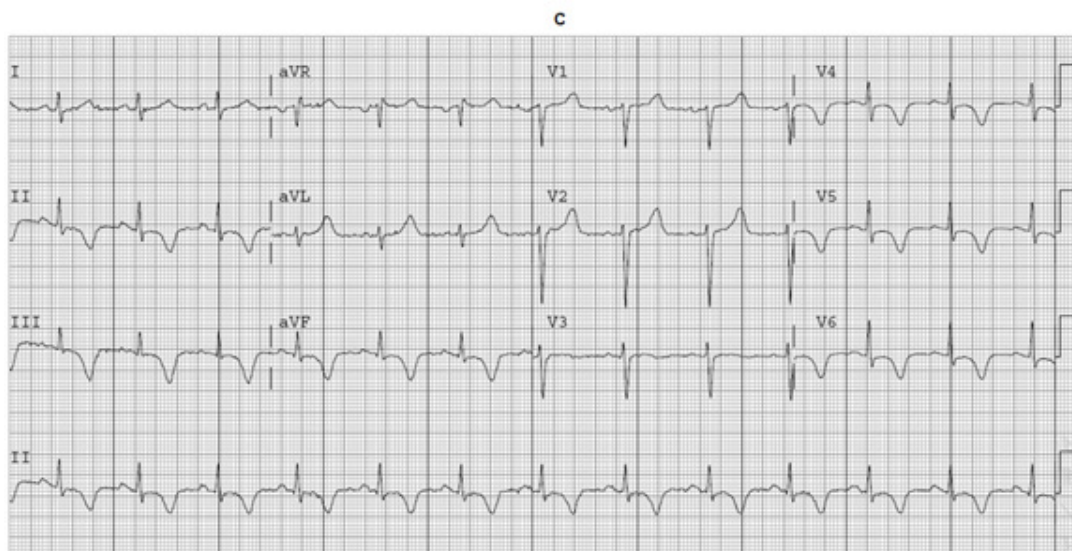
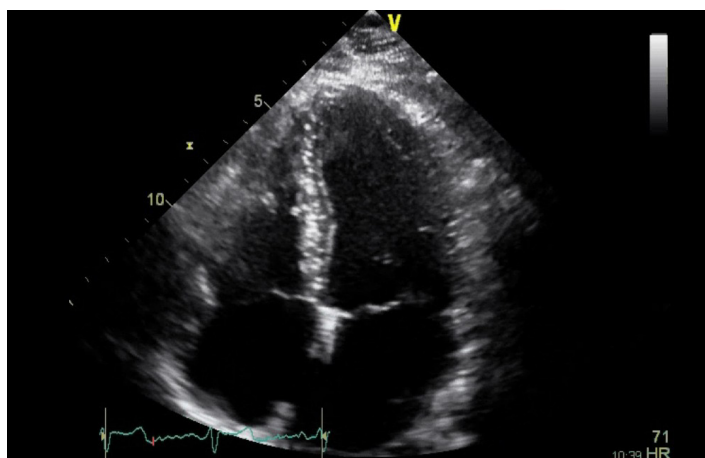


Fig 2 Echo post intervention



To see the video click on the link

[CLICK HERE](#)



What is the most likely diagnosis and the likely intervention performed?

Substantiate your answer with facts and findings from the available images and ECGs. (50 words)

The answer should be sent to the email - hfaioffice@gmail.com

The winners will be contacted by our office. Please give your contact telephone number and address in the link.

www.hfai.co.in