




HEART FAILURE
ASSOCIATION OF INDIA

QUIZ 1
October 2020



Quiz of the Month Series

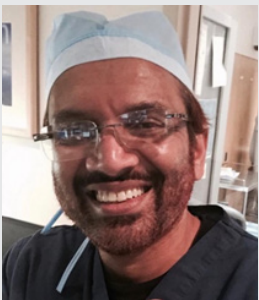Win attractive prizes.

5000 INR for the Winner

**Last date of submission
November 15, 2020**

Rules of the Quiz.

1. This is an image based Quiz. The image which is related to heart failure will follow a question with 4 responses, A,B,C and D.
2. The participant should mark the correct choice (A/B/C/D) and provide explanation why he chose that answer in 100 words.
3. The Quiz Master will select the First person who had given the correct answer with the correct explanation.
4. The decision of the Quiz master is final and no further deliberations in any form are allowed.
5. The winner will get a digital certificate and a Cash Prize of 5000 INR.



The Quiz of October 2020 is by **Dr. Mohammed Najeeb Osman**, who is currently the Medical Director of Cardiovascular services at University Hospitals Geneva Medical Center of Case Western Reserve University, and holds combined appointment at the Cleveland Veteran Administration Medical Center, USA.

www.hfai.co.in

To participate in the Quiz

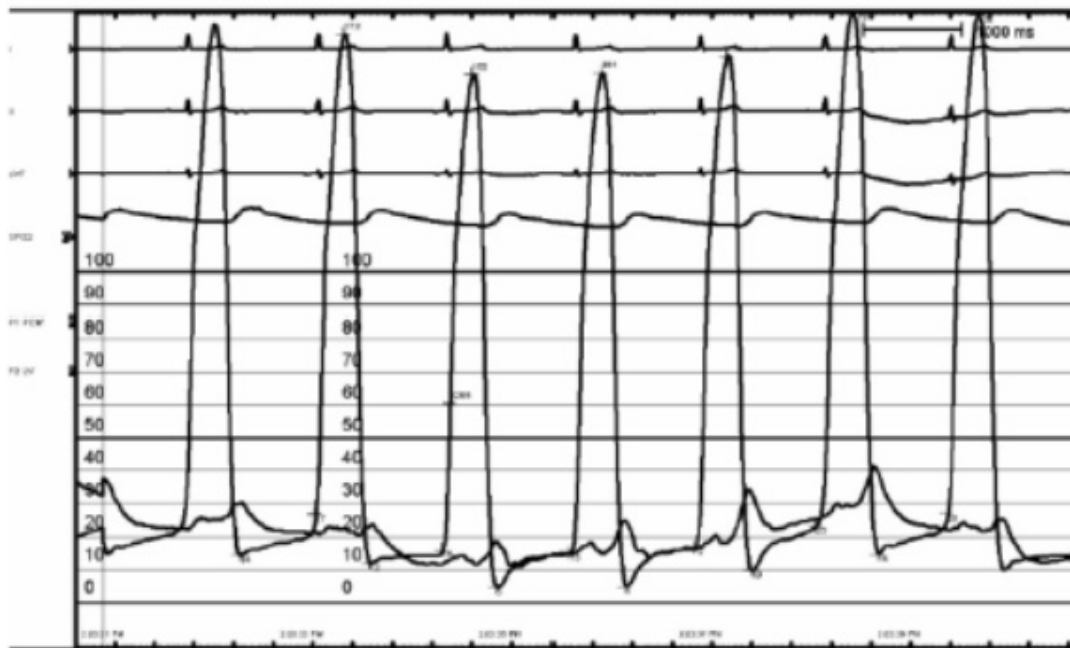
CLICK HERE



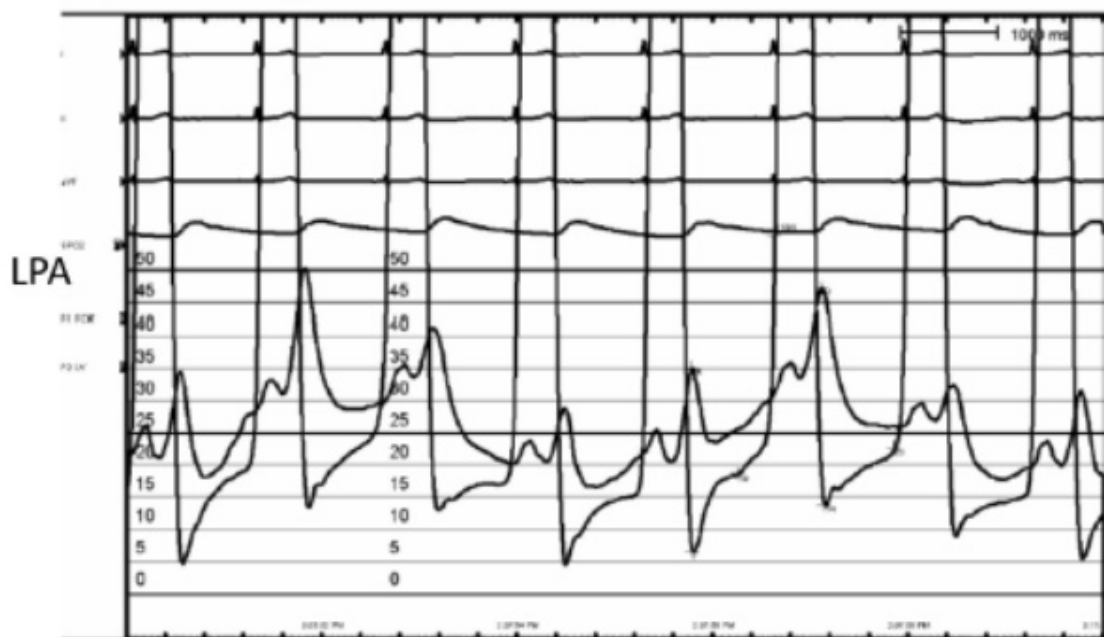
QUIZ 1

OCTOBER 2020

Right pulmonary artery (RPA) Wedge and LV Pressure



Left pulmonary artery (LPA) Wedge and LV Pressure



In reference to the above cardiac catheterisation tracings and the details of the patient given below, select the best answer among the following 4 choices and give the explanation in less than 50 words.



55 year old Caucasian gentleman presenting with progressive exertional shortness of breath after a cardiac procedure, with preserved left ventricular systolic function. He underwent cardiac catheterization and part of the tracings are shown.

- A. He had undergone catheter directed thrombolysis in left pulmonary artery.
- B. He has undergone repair of Supra cardiac total anomalous pulmonary venous connection in his teens.
- C. . He has history of palpitations for which he had undergone catheter intervention
- D. He has undergone percutaneous mitral commissurotomy (PTMC) unsuccessfully.

The winners will be contacted by our office. Please give your contact telephone number and address in the link.

To participate in the Quiz

CLICK HERE

